

Consensus Recommendations for the Use of Hyperdiluted Calcium Hydroxyapatite (Radiesse) as a Face and Body Biostimulatory Agent

Ada Trindade de Almeida, MD*

Vinicius Figueredo, MD†

Ana Lúcia Gonzaga da Cunha,
MD‡

Gabriela Casabona, MD§

Joana Ribeiro Costa de Faria,
MD¶

Emerson Vicente Alves, MD||

Mauricio Sato, MD**

Adeíza Branco, MD††

Christine Guarnieri, MD||

Eliandre Palermo, MD||‡‡

Background: Calcium hydroxyapatite (CaHA) is a well-established collagen stimulator. In recent years, it has been increasingly used in hyperdiluted form as a biostimulatory agent rather than a volumizing filler to improve skin quality and firmness in both facial and corporal areas. However, guidelines on the techniques required to achieve optimal results are still lacking. The objective of this study was to develop a consensus recommendation for the safe and effective use of hyperdiluted CaHA for face and body biostimulation.

Methods: A team of 10 experts with extensive experience in dermal fillers and biostimulatory treatments for facial and body rejuvenation convened for a live meeting. Consensus was defined as approval by 70%–89% of all participants, whereas agreement of ≥90% denoted strong consensus.

Results: For most items, the group achieved a majority consensus. Recommendations have been provided for the face, neck, décolletage, buttocks, thighs, arms, abdomen, knees, and elbows with detailed injection techniques, providing information on insertion points, dosages, and volumes for both needle and cannula injections as well as the number of treatment sessions and intervals.

Conclusions: The expert consensus supports and provides guidance for the use of CaHA as a biostimulatory agent for face and body rejuvenation. However, further clinical studies are necessary to provide physicians with the best evidence for the best treatment practices. (*Plast Reconstr Surg Glob Open* 2019;7:e2160; doi: 10.1097/GOX.0000000000002160; Published online 14 March 2019.)

From the *Clínica de Dermatologia do Hospital do Servidor Público Municipal de São Paulo and Private Practice, São Paulo, Brazil; †Department of Dermatology, Cosmetic Unity, Universidade Federal de São Paulo, São Paulo, Brazil; ‡Cosmetic Unit, Faculdade de Medicina do ABC, Santo André, Brazil; §Beauty Beyond Skin Clinic, São Paulo, Brazil; ¶Dermatology Private Practice, Brasília, Brazil; ||Dermatology Private Practice, São Paulo, Brazil; **Dermatology Private Practice, Curitiba, Brazil; ††Dermatology Private Practice, Recife, Brazil; and ‡‡Department of Dermatology, Faculty of Medicine of the ABC Foundation, Santo André, São Paulo, Brazil. Received for publication October 11, 2018; accepted December 13, 2018.

This manuscript was prepared according to the International Society for Medical Publication Professionals' Good Publication Practice for Communicating Company-Sponsored Medical Research: the GPP3 Guidelines.

The content of the publication reflects the experts' independent opinions and experiences.

Copyright © 2019 The Authors. Published by Wolters Kluwer Health, Inc. on behalf of The American Society of Plastic Surgeons. This is an open-access article distributed under the terms of the Creative Commons Attribution-Non Commercial-No Derivatives License 4.0 (CCBY-NC-ND), where it is permissible to download and share the work provided it is properly cited. The work cannot be changed in any way or used commercially without permission from the journal.

DOI: 10.1097/GOX.0000000000002160

INTRODUCTION

Following the successful expansion of noninvasive rejuvenative procedures for the face, a demand for nonsurgical rejuvenation options for nonfacial areas is also growing. Radiesse (Merz North America, Raleigh, N.C.) is a biocompatible, biodegradable, and resorbable biostimulatory filler containing calcium hydroxyapatite

Disclosure: The participants have disclosed financial relationships with the following companies: Dr. de Almeida is a speaker, consultant, and researcher for Merz Pharmaceuticals and Allergan; a consultant for Hypermarcas; and a researcher for Galderma S.A. Drs. Figueredo, Costa de Faria, and da Cunha are speakers and consultants for Merz Pharmaceuticals. Dr. Palermo is a speaker for Merz Pharmaceuticals and Galderma S.A. Dr. Alves is a speaker for Merz Pharmaceuticals and Vydence Medical. Dr. Guarnieri is a speaker and consultant for Galderma S.A. and Merz Pharmaceuticals. Dr. Sato is a speaker, consultant, and researcher for Merz Pharmaceuticals, and a speaker and researcher for Galderma S.A. Dr. Casabona is a speaker, consultant, and researcher for Allergan and Merz Pharmaceuticals. Dr. Branco is a speaker for Merz Pharmaceuticals. Funding to support the consensus meeting and preparation of this manuscript was provided by Merz Pharmaceuticals Brazil.

(CaHA) microspheres that can stimulate the endogenous production of collagen. It is a unique product that provides both volume replacement and collagen biostimulation as a primary mechanism of action.¹ Initial augmentation is afforded by the presence of the carrier carboxymethylcellulose gel with the implant itself, but after approximately 9–12 months, the CaHA particles are degraded into calcium and phosphate and are eliminated through the renal system.^{2–6} A highly viscoelastic CaHA filler used undiluted or slightly diluted provides immediate correction that is gradually followed by new tissue formation through neocollagenesis, elastin production, angiogenesis, and dermal cell proliferation and is well suited for supraperiosteal and subdermal placement.^{6,7} The result is a long-lasting aesthetic improvement for ≥ 18 months with tight and elastic skin and increased skin thickness.^{6,7}

When used in hyperdiluted form (ie, 1.5 mL of product plus ≥ 1.5 mL of diluent), Radiesse has a minimal or absent immediate volumizing effect due to carboxymethylcellulose gel dispersion, generating only long-term tissue remodeling by the CaHA microspheres and allowing its injection more superficially for dermal rejuvenation and the treatment of larger areas.^{3,7,8}

This article presents consensus recommendations for hyperdiluted application of CaHA (Radiesse) in both facial and nonfacial areas.

METHODS

A team of 10 experts in the fields of dermatology and plastic surgery with extensive experience with dermal fillers for facial and body rejuvenation convened in November 2017 for a full-day meeting in São Paulo, Brazil. A questionnaire distributed before the meeting and answered by the experts served as the basis for knowledge regarding medical management with this product and subsequent discussion. The meeting followed a structured consensus approach conducted by an experienced moderator.

“Strong consensus” was defined as agreement of $\geq 90\%$, whereas “consensus” was defined as approval ranging from 70% to 89% of all participants.

Suggestions and recommendations focused on providing directions for the use of hyperdiluted CaHA for the face, neck, décolletage, buttocks, thighs, arm, abdomen, knee, and elbow with detailed injection techniques, providing information on insertion points, dosages, and volumes for both needle and cannula injections and the number of required treatment sessions and intervals between them.

CaHA as a Biostimulatory Agent

Since 2004, evidence has indicated that the long-lasting effect of CaHA is secondary to a controlled inflammatory process that generates a predominantly fibroblastic reaction with replacement of the aqueous gel by a dense deposit of collagen.⁹ Berlin et al.⁴ observed that the main type of deposit is type 1 collagen, which is associated with improved mechanical properties of the skin, rather than type 3 collagen, which may be associated with fibrotic pro-

cesses. It was also observed that CaHA produced more type 1 collagen and elastin and resulted in a greater proliferation of fibroblasts compared with hyaluronic acid.¹⁰ Couderot et al.¹¹ noticed that in addition to fibroblast proliferation, CaHA also improved contractile function. Another study¹² using CaHA in a dilution of 1:1 reported a peak for type 1 collagen production in samples treated with the hyperdiluted product alone or in combination with *microfocused ultrasound with visualization* (MFU-V). Yutskovskaya and Kogan⁷ observed through immunohistochemical analysis that even when used in large dilutions (1:2 to 1:6), Radiesse was effective in increasing the production of type 1 collagen and elastin 7 months after injection and found that it improved neck and décolletage laxity after 2 sessions with a 4-month interval. Pavicic¹³ observed soft tissue enlargement on *magnetic resonance imaging* examination 2.5 years after injection even after complete absorption of the CaHA particles. Clinically, Silvers et al.⁶ demonstrated an increase in skin thickness by 50% after 3 months of application, which was maintained in 91% of subjects during the 18-month evaluation period. Wasylkowski¹⁴ reported improved laxity and dermal thickness of the abdominal region, arms, and thighs with treatment as soon as 5 weeks after the procedure. Additionally, in 2015, Amselem¹⁵ observed improvement of arm laxity after 2 treatment sessions separated by 1 month. To conclude, in 2016 2 consensus meetings on combinations of procedures for the face and body suggested the use of hyperdiluted CaHA for dermal rejuvenation in large areas.^{3,8}

Anesthesia and Dilutions

Pain management is an important issue to consider during aesthetic procedures. In 2009, the Food and Drug Administration approved a protocol for mixing CaHA with lidocaine at a concentration of 0.3% to improve patient comfort during injection.¹⁶ Many experts have developed techniques for using higher dilutions of CaHA, exploiting its collagen-stimulating effects to reduce skin laxity but without a volumizing effect.⁷ Dilutions can be titrated depending on the thickness of a patient’s skin and the degree of tissue laxity to ensure smooth product placement.⁷ Besides the dilution with lidocaine, some of the experts use topical anesthetics before the procedure.

Needle or Cannula

Needles have the advantage of extreme movement precision. On the other hand, cannulas cause less trauma and allow treatment of larger areas at the selected injection depth. Van Loghem et al.¹⁷ compared the precision difference between using needle and cannula for supraperiosteal filler placement in a cadaver study. Using the cannula resulted in product confinement to the deep anatomic layers, whereas the sharp needle technique resulted in material placement at multiple anatomic levels, from the periosteum to more superficial skin layers. In another study,¹⁸ 10 fresh-frozen cephalic foreheads were injected with radiopaque material using both needles and cannulas, followed by an imaging study with fluoroscopy, computed tomography, and magnetic resonance imaging. In

60% of the injections using a needle, the implanted material changed its plane. Therefore, both studies concluded that using cannulas resulted in more precise placement of the injected material compared with needles. The authors of the consensus considered the possibility of using a blunt cannula or a sharp needle while bearing in mind that with the use of needles, there is a greater risk of superficial placement of the product; therefore, this procedure must be carried out very carefully.

General Consensus Statements on the Aims of Treatment With CaHA

According to consensus members, the following general guidelines for treatment with hyperdiluted CaHA were established. These statements reached *strong consensus* (agreement of $\geq 90\%$) among the expert group members (Table 1).

Face

Soft tissue fillers offer a versatile, nonsurgical option for facial augmentation and contouring with a multitude of potential aesthetic applications.¹⁹ Volume loss and displacement of facial fat pads associated with ligament laxity cause skin drooping over a changing bony skeleton.²⁰ Skin aging is related to increased activity of endogenous enzymes, among other factors, that promote the breakdown of collagen and elastin fibers.^{21,22} The properties of Radiesse provide it with substantial versatility and appropriateness for most aspects of facial rejuvenation, volume restoration, contouring, and skin tightening. In the authors' experience, Radiesse diluted 1:1 can improve acne scars with minimal volume gain,²³ and hyperdiluted use allows the health-care professional to offer patients more global treatment rather than local filling/volumization, as the product can be more easily spread on the skin, providing general skin tightening with progressive, natural, and discrete volume gains (Fig. 1).

Current Practice and Consensus Statements for Face Treatment

According to experts, the following guidelines for face treatment with CaHA were established. The product can be applied via retroinjection using cannulas and fanning or "asterisks" techniques with 2–4 entry points in each hemiface. With needles, the short linear threading technique is preferred (Fig. 2, Table 1). For face treatment, a dilution of 1:1 (1.5 mL of diluent) and usually 1 syringe per session are indicated (Table 1).

Neck and Décolletage

Rejuvenation procedures for the neck and décolletage have increased substantially in recent years. Although CaHA use for neck and décolletage treatment is off-label, its ability to induce extracellular matrix remodeling after subdermal injection may have a significant impact on reducing fine wrinkling, improving skin quality, and promoting local skin tightening.^{8,24} In one study,²⁴ the authors described a technique for addressing horizontal neck lines by injecting hyperdiluted CaHA. Another trial⁷ evaluated the stimulating effects of diluted CaHA in subjects with skin laxity in the neck and décolletage. Twenty subjects

received subdermal injections of CaHA with different dilutions of preserved saline at baseline and after 4 months according to skin thickness: 1:2 (normal skin), 1:4 (thin skin), and 1:6 (atrophic skin). Changes in skin mechanical properties were measured by ultrasound scanning and cutometry. Immunohistochemical data showed increased collagen and elastin production correlated with improved skin elasticity and pliability, as evaluated by cutometry, and ultrasound revealed increased dermal thickness. Subject and investigator satisfaction were high, and the procedure was well tolerated.

Current Practice and Consensus Statements for Neck Treatment

According to the experts, the following guidelines for neck treatment with CaHA were established. Product application can be performed by cannula via retroinjection with 3–5 entrance points (Fig. 3, Table 1). The short linear threading technique with a needle is an alternative technical option. For neck treatment, a dilution of 1:2 to 1:4 (3–6 mL of diluent) is usually indicated according to the patient's skin thickness. Usually, 1 syringe per session is indicated (Table 1).

Current Practice and Consensus Statements for Décolletage Treatment

The following guidelines for CaHA décolletage treatment were established. It can be performed by the short linear threading technique with needle or via retroinjections with a cannula (Table 1). Generally, a dilution of 1:2 to 1:4 (3–6 mL of diluent) is indicated according to the patient's skin thickness. Usually, 0.5–1 syringe per session is indicated (Table 1).

Buttocks and Thighs

Buttocks and thighs play an important role in maintaining or improving body contours. Individuals present with a wide range of complaints: generalized lipohypertrophy or lipohypotrophy, gluteal sagging, and cellulite-induced skin-surface irregularities, among other complaints.^{8,25–27} Increasing the strength and elasticity of the dermis and superficial fascia is an important aim when treating skin laxity and cellulite dimples. CaHA injections have unequivocally demonstrated collagen-stimulating properties and improvements in skin laxity in different aesthetic applications.¹² When used with MFU, the biostimulatory effects of both treatments can be synergistic. One study¹² evaluated the effects of MFU-V in combination with diluted Radiesse on cellulite appearance. Twenty women with cellulite and skin laxity on the thighs and buttocks were retrospectively enrolled. MFU-V was applied and immediately followed by subdermal CaHA injection (1.5 mL/buttock or thigh). Two independent evaluators reported statistically significant improvements 90 days after treatment for each item of the cellulite severity scale ($P < 0.001$). This combination treatment was considered effective for improving the appearance of cellulite and skin laxity. In the authors' experience, the use of Radiesse alone (1.5 mL diluted with 6 mL of diluent) can also improve skin tightening and the appearance of cellulite dimples.

Table 1. General Consensus Statements

General Consensus Statements	
For CaHA biostimulation/skin tightening, 2–3 sessions are usually recommended spaced at 1–2 mo intervals.	
The preferred CaHA dilution for biostimulation/skin tightening treatment may change according to the treated area, degree of laxity, and skin thickness.	
The higher the dilution used, the smaller the immediate volumizing effect.	
It is possible that when more diluted CaHA is used and distributed into large areas, further treatment sessions will be required.	
It is possible that higher dilutions provide a lower risk of nodule formation due to product accumulation.	
The literature shows that CaHA acts as a collagen and elastin biostimulator when used undiluted or diluted up to 1:6 (9 mL of diluent to 1.5 mL of product). However, the existing data are insufficient to certify that one dilution is superior to the other in the final stimulation of collagen.	
The relationship between the size of the area to be treated and the amount of product used may vary according to local tissue characteristics, anatomical features, and local degree of laxity. Usually 1 syringe (1.5 mL) is used to treat an area of 100–300 cm ² . When using a cannula, the amount of product per passing is around 0.1–0.2 mL and with needle is of 0.1 mL, with a distance between the linear injection of 2 cm.	
For dilution of CaHA, 0.5–1.5 mL of 2% lidocaine with or without epinephrine may be used. If larger dilutions are needed, then saline solution is added to achieve the desired final volume.	
The recommended cannulas are usually 22–25 gauge.	
The recommended needles are usually 27–30 gauge.	

Table 2. Consensus Statements

Statements for Facial Treatment	Agreement (%)
Strong consensus	
Product application can be performed via retroinjection using a cannula in a fanning or asterisk technique, with 2–4 entry points per facial side.	100
For facial treatments, the preferred dilution is 1:1 (1.5 mL of diluent).	90
A short linear threading technique with a needle can be used.	90
Consensus	
Usually 1 syringe per session is indicated.	80
Statements for Neck Treatment	
Strong consensus	
Usually 1 syringe per session is indicated.	100
Product application can be performed by cannula via retroinjection (fanning or asterisk technique) with 3–5 entrance points.	100
Consensus	
For neck treatment, a dilution of 1:2 to 1:4 (3–6 mL of diluent) is usually indicated according to the patient’s skin thickness.	80
A short linear threading technique using a needle is an alternative option.	80
Statements for Décolletage Treatment	
Strong consensus	
Décolletage treatment can be performed by short linear threading technique with a needle or by cannula retroinjections (fanning or asterisk).	100
Usually 0.5–1 syringe per session is indicated.	100
Consensus	
For décolletage treatment, the dilution of 1:2 to 1:4 (3–6 mL of diluent) is indicated according to the patient’s skin thickness.	80
Statements for Buttocks Treatment	
Strong consensus	
For skin laxity of the buttocks, the suggested technique is cannula fanning or asterisk injection.	100
The product should be applied mainly on the upper and lateral portion of the buttocks and on cellulite dimples.	100
Usually 1 syringe per each side of the buttocks per session is indicated.	100
For skin laxity of the buttocks, the dilution may range from 1:1 to 1:4 (1.5–6 mL of diluent).	100
For cellulite dimples, lower dilutions (1:1 or 1:2) can be used.	90
A short linear threading technique with a needle can be used.	90
Statements for Thigh Treatment	
Strong consensus	
The product can be applied to the inner and posterior thigh areas.	100
Usually 1 syringe per thigh area (inner or posterior) is indicated.	100
The recommended CaHA dilution may range from 1:1 to 1:4 (1.5–6 mL of diluent) according to the degree of laxity.	100
The most used technique for skin laxity is multiple cannula passages via fanning or asterisk injections.	90
A short linear threading technique with a needle can also be used.	90
Statements for Abdominal Treatment	
Strong consensus	
Product dilution can range from 1:1 to 1:4 (1.5–6 mL of diluent).	100
CaHA injections can be performed by cannula (fanning or asterisk technique) distributed to 4 stomach quadrants.	90
A short linear threading technique may also be used with a needle.	90
A short linear threading technique with a needle is particularly indicated for the periumbilical region.	90
Consensus	
Usually one syringe is indicated for the upper abdominal region and another is needed for the lower portion.	80
Statements for Arm Treatment	
Strong consensus	
Usually 0.5–1 syringe per arm is indicated in each session.	100
Preferred dilution range is 1:2 to 1:4 (3–6 mL of diluent).	90
Recommended technique is fanning retroinjection with cannula, with 2–4 entry points distributed along the inner arm.	90

(Continued)

Table 2. (Continued)

Statements for Knee Treatment	
Strong consensus	
Product application can be performed by fanning retroinjection with cannula or by short linear threading technique with needles.	100
Treatment is suggested mainly for the region located above the patella.	100
Consensus	
Recommended dose per session is 1 syringe in total (half per side).	80
Statements for Elbow Treatment	
Strong consensus	
Treatment is suggested mainly for the superior region of the elbow.	100
Product application can be performed by injecting the product in a short linear threading technique with a needle.	90
It is recommended 1 syringe in total (half per side) per session.	90
Follow-up Treatment	
Strong consensus	
After the initial treatment cycle, 1 follow-up session is suggested, within 12–18 mo.	100
Massage	
Strong consensus	
The initial massage should be performed by the physician after the procedure with the aim of achieving an even spread of the product in the treated area.	100
Consensus	
Self-massage can be recommended for the patient at the injection site (twice a day for 3–7 d).	80

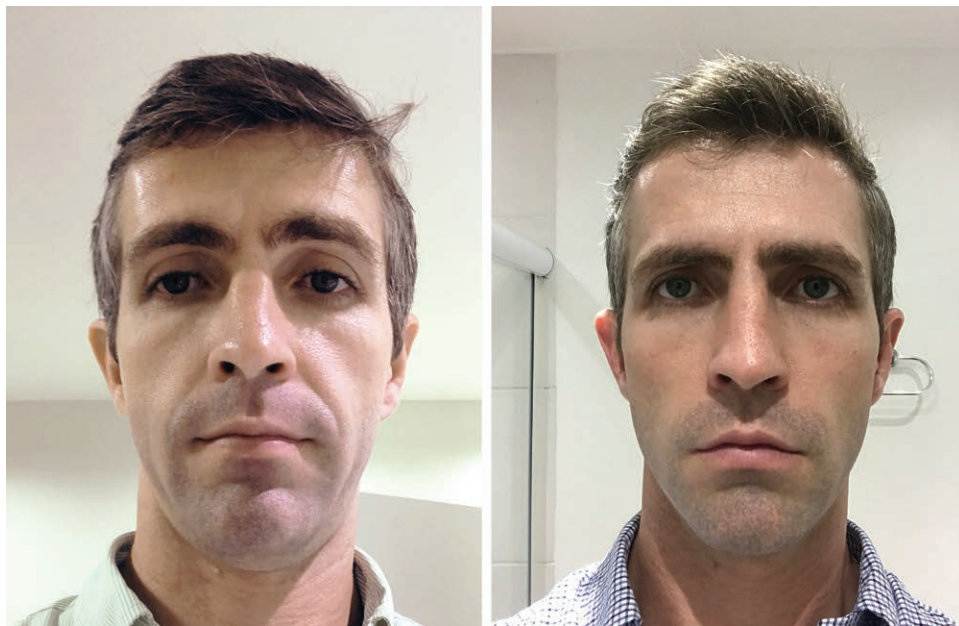

Fig. 1. The face before and 8 weeks after injections of 1.5 mL of CaHA (Radiesse) diluted 1:1 with 1.5 mL of lidocaine (total of 3 syringes split in 2 sessions with a 4-week interval). Notice the improvement of skin laxity and the discrete volume gain. Courtesy of Vinicius Figueredo, MD.

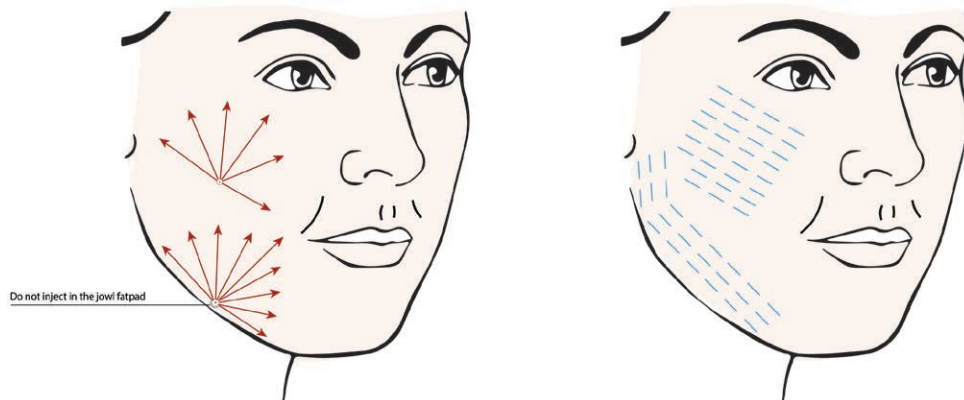


Fig. 2. Techniques for CaHA biostimulation of the face.

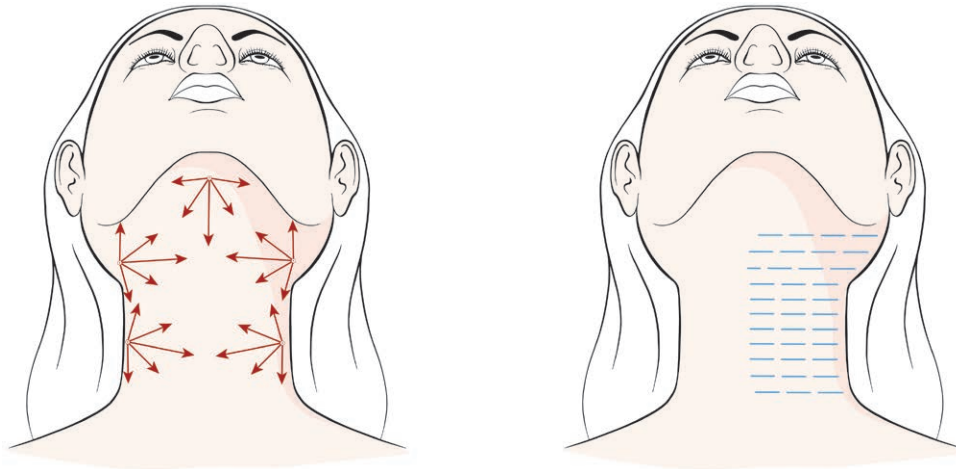


Fig. 3. Techniques for CaHA biostimulation of the neck.

Current Practice and Consensus Statements on Buttocks Treatment

The following guidelines for CaHA buttocks treatment were established. For buttocks skin laxity, the product can be applied with a cannula using the fanning or asterisks technique. The product should be applied mainly on the upper and lateral portions of the buttocks and on cellulite dimples (Figs. 4, Table 1). The short linear threading technique can also be used with needles. Usually, 1 syringe per buttock side per session is indicated. For buttocks skin laxity, the dilution may range from 1:1 to 1:4 (1.5–6 mL of diluent), whereas for cellulite dimples, lower dilutions (1:1 or 1:2) can be used (Table 1).

Current Practice and Consensus Statements on Thighs Treatment

The following guidelines for CaHA thigh treatment were established. The product can be applied to the inner and posterior thigh areas. The most frequently used technique for skin laxity is multiple cannula passages with fanning or asterisks injections (Table 1). The short linear threading technique can also be used with needles. Usually, 1 syringe per thigh area (inner or posterior) is indicated. The recommended CaHA dilution may range from

1:1 to 1:4 (1.5–6 mL of diluent) according to the degree of laxity (Table 1).

Abdomen (Stomach)

A body-vectoring technique using CaHA injections demonstrated notable reductions in skin flaccidity and increases in skin density and thickness in the abdomen and thighs 5 weeks after 1 treatment session.²⁸ In 2017, Lapatina and Pavlenko²⁹ evaluated the effectiveness of hyperdiluted CaHA for skin tightening in a case series of 10 women with skin laxity in the abdomen using ultrasound. CaHA diluted 1:4 with saline solution was injected subdermally using the linear threading technique, and the authors concluded that CaHA improved skin elasticity and increased abdominal dermal thickness after only a single treatment.

Current Practice and Consensus Statements of Abdomen Treatment

The following guidelines for CaHA abdomen treatment were established. Product application can be performed by both cannulas (the fanning or asterisk technique) and needles (short linear threading) with distribution across 4 abdominal quadrants (Fig. 5,

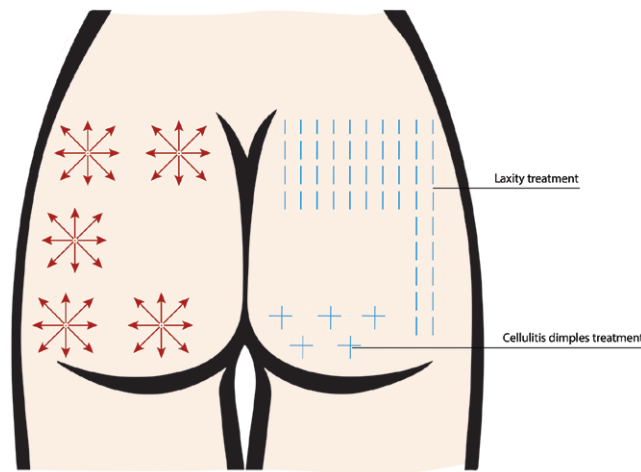


Fig. 4. Techniques for CaHA application in the buttocks.

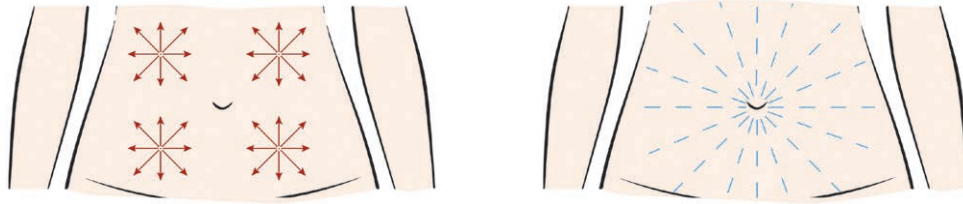


Fig. 5. Techniques for CaHA application in the abdomen.

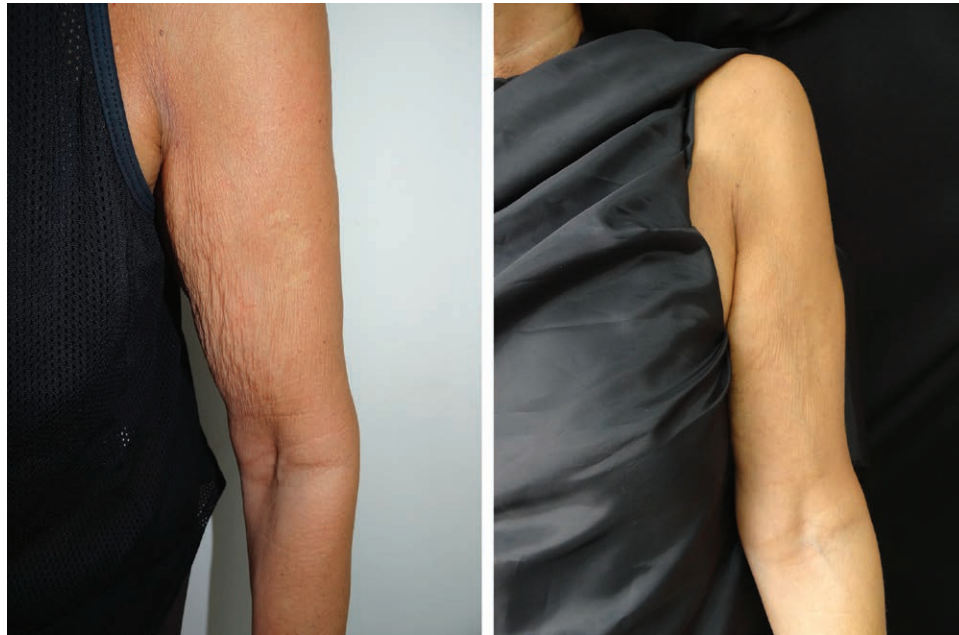

Fig. 6. The upper arm before and 48 weeks after injection of 1.5 mL of CaHA (Radiesse) diluted with 6 mL of lidocaine, per side. Notice the remarkable long-term improvement of skin laxity. Courtesy of Eliandre Palermo, MD.

Table 1). The short needle linear threading technique is particularly indicated for the periumbilical region. Product dilution can range from 1:1 to 1:4 (1.5–6 mL of diluent). Usually, one syringe is indicated for the upper abdominal region and another one is required for the lower half per session (Table 1).

Arms

As part of the natural aging process, the skin elasticity and firmness of the upper arms begin to decrease, increasing the visibility of some signs of aging, such as loose-hanging skin and fine wrinkles. In a prospective study,¹⁵ 30 subjects received CaHA injections to the upper arms (1.5 mL/arm/visit) at 2 separate visits 1 month apart. Four months after the second treatment, flaccidity and volume showed significant improvements, with 77% of the subjects rating the improvements as good or great. In another study,²⁹ improved skin elasticity of the arms was observed by cutometry after hyperdiluted 1:2 CaHA injection using the short linear threading technique (Fig. 6).

Current Practice and Consensus Statements on Arm Treatment

The generally recommended technique is retroinjection with a cannula with 2–4 fanning injections distributed

along the inner arm (Fig. 7, Table 1). Usually, 0.5–1 syringe per arm is indicated per session. The preferred dilution range is from 1:2 to 1:4 (3–6 mL of diluent) (Table 1).

Knees and Elbows

The knees and elbows show increased laxity with age. Although no clinical studies are available regarding CaHA treatment of these areas, in the authors' experience, the local aged appearance can be improved by CaHA-generated collagen stimulation.

Current Practice and Consensus Statements on Knee Treatment

Product application can be performed via retroinjection with fanning with a cannula or by the short linear threading technique with needles. Treatment is suggested mainly for the region located above the patella. The recommended dose per session is 1 syringe in total (half per side) (Fig. 8, Table 1). No consensus was reached on the dilution used for the knees, but the authors presented their experiences with different dilutions ranging from 100% (1.5 mL) to 400% (6 mL).

Current Practice and Consensus Statements on Elbow Treatment

According to the experts, the following guidelines for CaHA elbow treatment were established. Product applica-

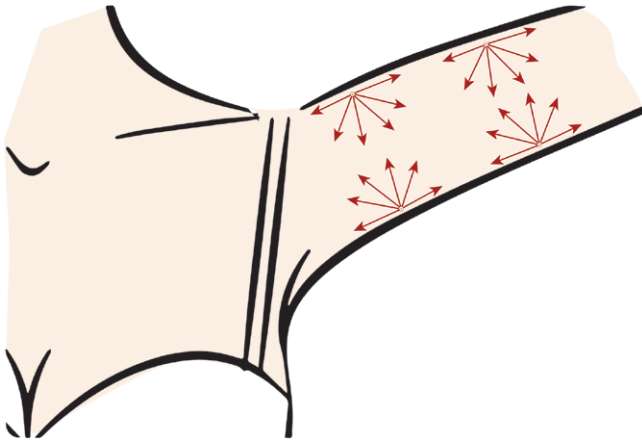


Fig. 7. Technique for CaHA application in the arm.

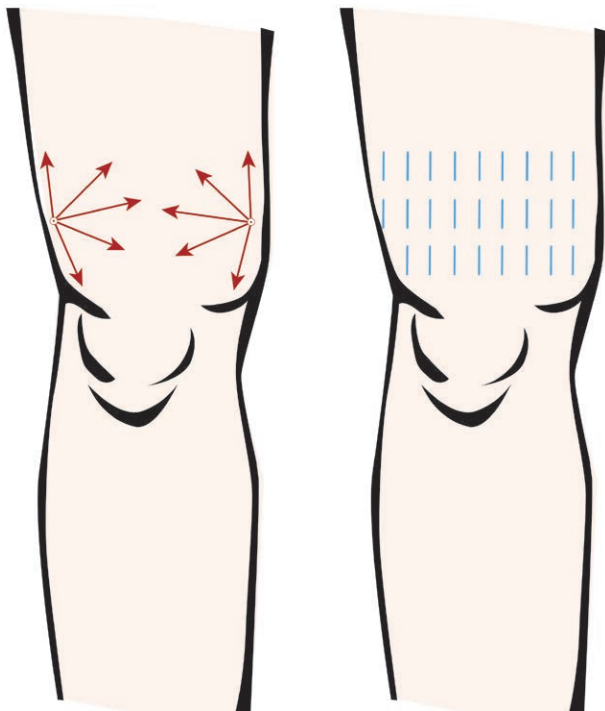


Fig. 8. Techniques for CaHA application in the knee.

tion can be performed by injecting the product with the short linear threading technique with a needle. The treatment is suggested mainly for the superior region of the elbow using 1 syringe in total (half per side) per session (Table 1).

Postprocedure, Adverse Events, and Follow-up Instructions

Exposure of the treated area to excessive sun and heat should be minimized for approximately 24 hours. A cold pack can be used to minimize tenderness, swelling, and bruising. During the treatment session, the treated area may need to be massaged to ensure that the CaHA is distributed evenly.³⁰ If nodules develop, they can be treated with lidocaine or saline followed by vigorous massage.

Nodules that do not resolve may respond to a series of ≥ 3 injections of 5-fluorouracil, triamcinolone, and lidocaine or 5-fluorouracil and lidocaine.³¹ Based on an extensive literature review of 5,081 treatments with CaHA by Kadouch,¹ the product appears to have a good safety profile. In this study,¹ 45% of the reported nodules occurred in dynamic areas of the face. The current data suggest that if dynamic areas of the face were avoided, the incidence of CaHA nodules would be substantially lower. For facial augmentation, although some concerns about tissue necrosis and serious complications such as embolization have been noted in the literature, no vascular compromise has been observed by the authors on their practice and by Kadouch. However, caution should be the rule when treating the face and the high risky areas like the glabellar region and nose should be avoided. Regarding effect duration, it may depend on many factors, such as the patient’s age and metabolism, and the relative dynamic motion of the area in which the implant is placed. Published data show CaHA treatment results lasting up to 18–24 months.³²

Current Practice and Consensus Statements

After an initial treatment cycle, one maintenance session is suggested within a range of 12–18 months. After the procedure, massage should be immediately performed by the physician to evenly distribute the product in the treated area. The patient can also be instructed to massage the injection site area 2 times a day for 3–7 days (Table 1).

CONCLUSIONS

Radiesse® (CaHA) is associated with a high and well-established safety profile and is a very effective agent for soft tissue augmentation of different face and body areas. The rising popularity of minimally invasive aesthetic procedures for the face over the last decade has led to greater demands for body rejuvenation interventions to minimize discrepancies between body and face appearance. The characteristic of Radiesse of long-term collagen stimulation reflects its substantial versatility. This consensus provides recommendations for the use of hyperdiluted CaHA as a biostimulatory agent for face and body rejuvenation and to improve skin quality and firmness.

Vinicius Figueredo, MD
 Rua Machado Bittencourt 300
 São Paulo, SP, Brazil
 CEP 04044000
 E-mail: vinoliveira@msn.com

ACKNOWLEDGMENT

The authors wish to thank Jessica Notario for providing medical writing and editorial assistance on behalf of Springer Healthcare.

REFERENCES

1. Kadouch JA. Calcium hydroxylapatite: a review on safety and complications. *J Cosmet Dermatol.* 2017;16:152–161.
2. Loghem JV, Yutskovskaya YA, Philip Werschler W. Calcium hydroxylapatite: over a decade of clinical experience. *J Clin Aesthet Dermatol.* 2015;8:38–49.

3. Carruthers J, Burgess C, Day D, et al. Consensus recommendations for combined aesthetic interventions in the face using botulinum toxin, fillers, and energy-based devices. *Dermatol Surg*. 2016;42:586–597.
4. Berlin AL, Hussain M, Goldberg DJ. Calcium hydroxylapatite filler for facial rejuvenation: a histologic and immunohistochemical analysis. *Dermatol Surg*. 2008;34(suppl 1):S64–S67.
5. Tzikas TL. A 52-month summary of results using calcium hydroxylapatite for facial soft tissue augmentation. *Dermatol Surg*. 2008;34(suppl 1):S9–S15.
6. Silvers SL, Eviatar JA, Echavez MI, et al. Prospective, open-label, 18-month trial of calcium hydroxylapatite (Radiesse) for facial soft-tissue augmentation in patients with human immunodeficiency virus-associated lipoatrophy: one-year durability. *Plast Reconstr Surg*. 2006;118(suppl):34S–45S.
7. Yutskovskaya YA, Kogan EA. Improved neocollagenesis and skin mechanical properties after injection of diluted calcium hydroxylapatite in the neck and décolletage: a pilot study. *J Drugs Dermatol*. 2017;16:68–74.
8. Fabi SG, Burgess C, Carruthers A, et al. Consensus recommendations for combined aesthetic interventions using botulinum toxin, fillers, and microfocused ultrasound in the neck, décolletage, hands, and other areas of the body. *Dermatol Surg*. 2016;42:1199–1208.
9. Coleman KM, Voigts R, DeVore DP, et al. Neocollagenesis after injection of calcium hydroxylapatite composition in a canine model. *Dermatol Surg*. 2008;34(suppl 1):S53–S55.
10. Yutskovskaya Y, Kogan E, Leshunov E. A randomized, split-face, histomorphologic study comparing a volumetric calcium hydroxylapatite and a hyaluronic acid-based dermal filler. *J Drugs Dermatol*. 2014;13:47–52.
11. Courderot-Masuyer C, Robin S, Tauzin H, et al. Evaluation of lifting and antiwrinkle effects of calcium hydroxylapatite filler. In vitro quantification of contractile forces of human wrinkle and normal aged fibroblasts treated with calcium hydroxylapatite. *J Cosmet Dermatol*. 2016;15:260–268.
12. Casabona G, Pereira G. Microfocused ultrasound with visualization and calcium hydroxylapatite for improving skin laxity and cellulite appearance. *Plast Reconstr Surg Glob Open*. 2017;5:e1388.
13. Pavicic T. Complete biodegradable nature of calcium hydroxylapatite after injection for malar enhancement: an MRI study. *Clin Cosmet Investig Dermatol*. 2015;8:19–25.
14. Wasylkowski VC. Body vectoring technique with Radiesse for tightening of the abdomen, thighs, and brachial zone. *Clin Cosmet Investig Dermatol*. 2015;8:267–273.
15. Amselem M. Radiesse: a novel rejuvenation treatment for the upper arms. *Clin Cosmet Investig Dermatol*. 2015;9:9–14.
16. Grunebaum LD, Elsaie ML, Kaufman J. Six-month, double-blind, randomized, split-face study to compare the efficacy and safety of calcium hydroxylapatite (CaHA) mixed with lidocaine and CaHA alone for correction of nasolabial fold wrinkles. *Dermatol Surg*. 2010;36:760–765.
17. van Loghem JA, Humzah D, Kerschner M. Cannula versus sharp needle for placement of soft tissue fillers: an observational cadaver study. *Aesthet Surg J*. 2017;38:73–88.
18. Pavicic T, Frank K, Erlbacher K, et al. Precision in dermal filling: a comparison between needle and cannula when using soft tissue fillers. *J Drugs Dermatol*. 2017;16:866–872.
19. Beer K. Dermal fillers and combinations of fillers for facial rejuvenation. *Dermatol Clin*. 2009;27:427–432, v.
20. Carruthers J, Carruthers A. Botulinum toxin A in the mid and lower face and neck. *Dermatol Clin*. 2004;22:151–158.
21. Rohrich RJ, Pessa JE. The fat compartments of the face: anatomy and clinical implications for cosmetic surgery. *Plast Reconstr Surg*. 2007;119:2219–2227; discussion 2228.
22. Rohrich RJ, Pessa JE, Ristow B. The youthful cheek and the deep medial fat compartment. *Plast Reconstr Surg*. 2008;121:2107–2112.
23. Casabona G. Combined use of microfocused ultrasound and a calcium hydroxylapatite dermal filler for treating atrophic acne scars: a pilot study. *J Cosmet Laser Ther*. 2018;5:301–306.
24. Chao YY, Chiu HH, Howell DJ. A novel injection technique for horizontal neck lines correction using calcium hydroxylapatite. *Dermatol Surg*. 2011;37:1542–1545.
25. Mazzucco R, Sadick NS. The use of poly-L-lactic acid in the gluteal area. *Dermatol Surg*. 2016;42:441–443.
26. Goldberg DJ, Hornfeldt CS. Safety and efficacy of microfocused ultrasound to lift, tighten, and smooth the buttocks. *Dermatol Surg*. 2014;40:1113–1117.
27. Sasaki G, Tevez A. Microfocused ultrasound for nonablative skin and subdermal tightening to the periorbit and body sites: preliminary report on eighty-two patients. *J Cosmet Dermatol Sci Appl*. 2012;2:109–116.
28. Cogorno Wasylkowski V. Body vectoring technique with Radiesse for tightening of the abdomen, thighs, and brachial zone. *Clin Cosmet Investig Dermatol*. 2015;8:267–273.
29. Lapatina NG, Pavlenko T. Diluted calcium hydroxylapatite for skin tightening of the upper arms and abdomen. *J Drugs Dermatol*. 2017;16:900–906.
30. Day D. Counseling patients on facial volume replacement and adherence with posttreatment instructions. *Patient Prefer Adherence*. 2010;4:273–281.
31. Funt D, Pavicic T. Dermal fillers in aesthetics: an overview of adverse events and treatment approaches. *Clin Cosmet Investig Dermatol*. 2013;6:295–316.
32. Jacovella PF. Use of calcium hydroxylapatite (Radiesse) for facial augmentation. *Clin Interv Aging*. 2008;3:161–174.